

## PRRT as an alternative method of treatment in patient with glucagonoma syndrome: A case report

Popławska-Kita A.<sup>A-F\*</sup>, Szyszkowska A.<sup>C-F</sup>, Brelska P.<sup>C-F</sup>, Kowalczyk MA.<sup>C-F</sup>, Szostek A.<sup>C-F</sup>, Popławski Ł.<sup>C-F</sup>, Siewko K.<sup>A,E,F</sup>, Szelachowska M.<sup>E-F</sup>, Kamiński G.<sup>B,E</sup>, Werel D.<sup>B</sup>, Górska M.<sup>E-F</sup>

1. Department of Endocrinology, Diabetology and Internal Medicine, Medical University of Białystok, Poland
2. Department of Endocrinology and Nuclear Medicine, Military Institute of Medicine, Warsaw, Poland
3. Department of Radiology, Medical University of Białystok, Poland
4. Students' Research Group in the Department of Endocrinology, Diabetology and Internal Medicine, Medical University of Białystok, Poland

---

A - Conception and study design, B - Data collection, C –Data analysis, D - Writing the paper, E – Review article, F - Approval of the final version of the article

---

### ABSTRACT

---

**Introduction:** Glucagonoma is a rare pancreatic neuroendocrine tumor derived from alpha-cells of the islet of Langerhans. Due to oversecretion of glucagon it is associated with a characteristic paraneoplastic phenomenon, called glucagonoma syndrome, which consists of necrolytic migratory erythema (NME), weight loss, diabetes mellitus, diarrhea, normochromic normocytic anemia, deep vein thrombosis or pulmonary embolism and neuropsychiatric disturbances. Treatment modalities include surgical removal of tumor, somatostatin analogs and peptide receptor radionuclide therapy (PRRT).

**Case report:** We present a case of 61-year-old woman diagnosed with glucagonoma in April 2012. Initially, body-caudal pancreatectomy and resection of regional lymph nodes were performed. Five months

after surgery, a PET-CT scan detected pathological mass with expression of somatostatin receptors in pancreatic body and metastases to regional lymph nodes. What is more, since April 2014 the patient had complained about persistent pruritus of the entire body. At present, due to the nonsurgical pancreatic mass and metastases she is treated with somatostatin analogs and PRRT. During this therapy the pruritus had decreased and currently there is no sign of cutaneous disease. Moreover, reduction of tumor size was obtained.

**Conclusions:** PRRT may reduce tumor size and by reducing bothersome symptoms substantially improve the quality of life in patients with SSTR-positive tumors.

**Key words:** Glucagonoma, tumor, peptide receptor radionuclide therapy

---

DOI: 10.5604/01.3001.0010.1922

**\*Corresponding author:**

Anna Popławska-Kita  
Department of Endocrinology, Diabetology and Internal Medicine  
Medical University of Białystok, Skłodowskiej-Curie 24A  
15-276 Białystok, Poland  
Tel.: +48 604425324; Fax: +48 857461909

Received: 09.06. 2016

Accepted: 19.06.2016

Progress in Health Sciences

Vol. 6(1) 2016 pp 209-214

© Medical University of Białystok, Poland

## INTRODUCTION

Glucagonoma is a rare, slowly growing, frequently malignant pancreatic neuroendocrine tumor (NET) arising from alpha-cells of the islets of the Langerhans. In 1942, Becker, Kahn and Rothman first noticed an association between characteristic skin disorder and pancreatic tumor [1]. Then in 1966 McGavran et al. [1] discovered the origin of this disorder thanks to radioimmunoassay technique for glucagon and named this combination of symptoms as a glucagonoma syndrome [2]. Since its first description [1], around 300 cases of glucagonoma and glucagonoma syndrome have been described. The incidence of glucagonoma is estimated at 1 in 20 million [3]. The tumor is usually bigger than 5 cm [4] and the most common location of this lesion is the tail of the pancreas [3,5,6].

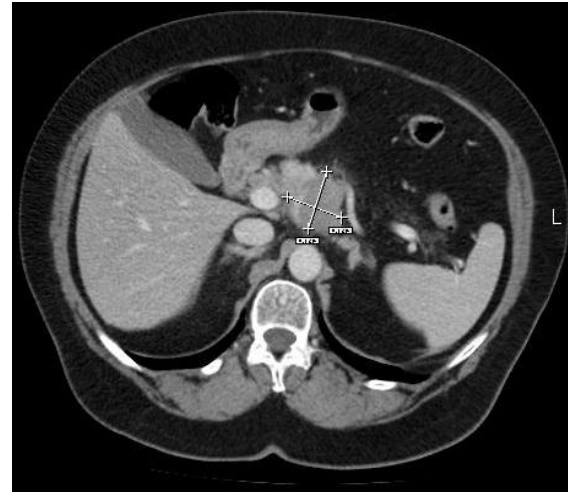
Glucagonoma, due to oversecretion of glucagon is associated with a characteristic paraneoplastic phenomenon, called glucagonoma syndrome, which consists of specific rash known as necrolytic migratory erythema (NME), mild diabetes mellitus (DM), weight loss, normochromic normocytic anemia, glossitis, stomatitis, hypoaminoacidemia, deep vein thrombosis and depression [7].

Diagnosis of this disorder is based on clinical features, laboratory tests, such as elevated glucagon serum level and visualization of the pancreatic tumor. Treatment modalities include surgical removal of tumor, somatostatin analogs and peptide receptor radionuclide therapy (PRRT) [5,7].

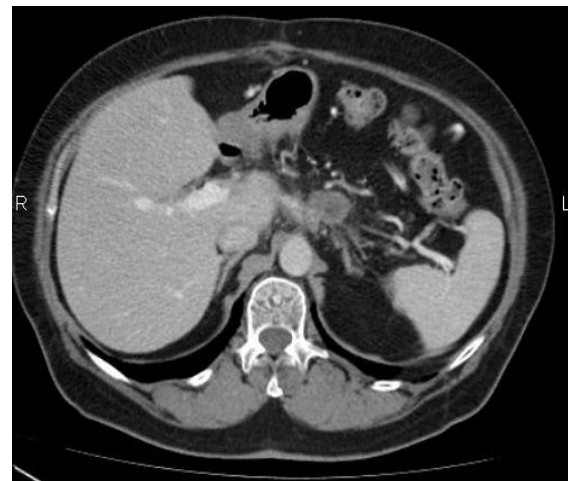
## Case report

In March 2012, a 61-year-old female was admitted to Department of Gastroenterology and Internal Medicine of Medical University of Bialystok due to intense abdominal pain, which was radiating to vertebral column. She also complained about vomiting, flatulence and bad general condition. The anamnesis revealed 4-year history of similar (but slighter) episodes of pain and the weight loss of about 20 kg over the past one year. Additionally, the patient had suffered from DM type 2 since 2010 and arterial hypertension for about 10 years. Glycemia level was well-controlled by metformin 500 mg twice a day. Upon physical examination there was pain in the upper and the middle abdomen, there was no visceromegaly or palpable masses. The patient had high blood pressure (180/95 mmHg). Admission laboratory tests demonstrated mild leukocytosis, elevated C-reactive protein concentration and pyuria. In the investigation, abdominal ultrasound, CT and upper gastrointestinal endoscopic ultrasonography were

performed, which disclosed a hypoechoic mass with several small calcifications and irregular margins on the pancreas topography of approximately 55 x 40 mm in size. The tumor was extending into splenic artery and vein. The tail of the pancreas was invisible, probably atrophied, the pancreatic head was normal. There were enlarged celiac lymph nodes of 7-8 mm and one hypoechoic lymph node of 11,5 mm above pancreatic head (suspicion of metastasis) (Fig.1).



**Figure 1.** Hypoechoic mass with several small calcifications and irregular margins on the pancreas topography of approximately 55 x 40 mm in size. The tumor was extending into splenic artery and vein. The tail of the pancreas was invisible, probably atrophied, the pancreatic head was normal. There were enlarged celiac lymph nodes of 7-8 mm and one hypoechoic lymph node of 11,5 mm above pancreatic head (suspicion of metastasis).



**Figure 2.** In November 2012, CT scan showed oval, marginal enhancing pancreatic mass of 26 x 21 x 23 mm, which could be cancer remains or recurrence. There were also slightly enlarged, non-homogenous enhancing paraaortic lymph node and hypodense nodules nearby the lesser curvature of the stomach.

Transesophageal biopsy was performed and pathological examination showed inflammatory cells and cells suspicious for malignancy.

Transesophageal biopsy was performed and pathological examination showed inflammatory cells and cells suspicious for malignancy. Chromogranin A concentration was 379,4 ng/ml (normal range 27-94ng/ml).

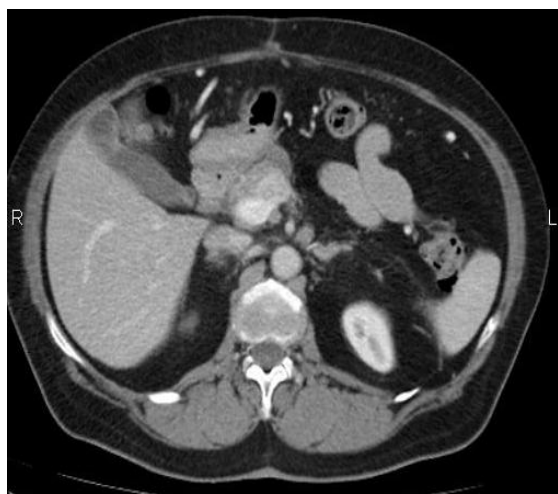
In April 2012, body-caudal pancreatotomy and resection of regional lymph nodes were performed. The tumor was spreading to the celiac trunk and to the inferior mesenteric vein. The histopathologic report revealed a neuroendocrine carcinoma with expression of glucagon, chromogranin A, synaptophysin and Ki 67 - 2%.

5 months after surgery a PET-CT scan detected pathological mass (23 x 14 mm in size) with expression of somatostatin receptors (SSTR) in pancreas and metastases to regional lymph nodes.

There was also a lesion of 26,6 x 22,5 mm without expression of SSTR. Estimated chromogranin A concentration was in the normal range (36,3ng/ml).

In November 2012, a contrast-enhanced CT scan showed oval, marginal enhancing pancreatic mass of 26 x 21 x 23 mm, which could be cancer remains or recurrence. There were also slightly enlarged, non-homogenous enhancing paraaortic lymph node (11 mm) and hypodense nodules (6-11 mm) nearby the lesser curvature of the stomach. (Fig.2). At that point, chromogranin A concentration increased up to 157,0ng/ml; 123,2ng/ml.

Due to the nonsurgical, SSTR-positive tumor somatostatin analog has been introduced to patient (Sandostatin LAR 30 mg) since December 2013 (on average once a month). During the treatment chromogranin A concentration stayed in the normal range (36,3ng/ml).

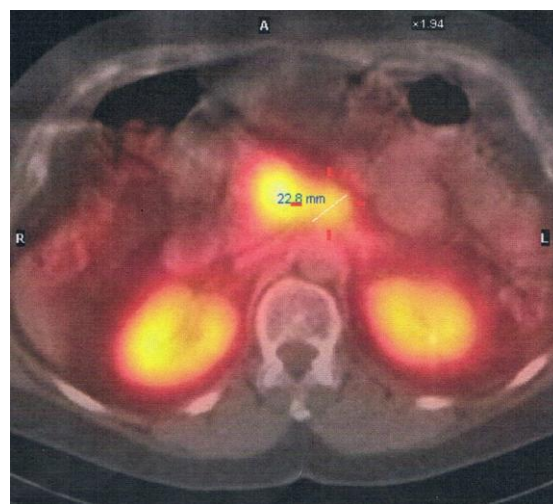


**Figure 3.** In March 2014, CT scan identified 20 x 18 mm oval mass with marginal calcification without evidence of enhancement. Nearby pancreatic head there was a hyperdense mass of 5 mm. In lesser curvature of the stomach area there was a tumor of 9 x 7 mm in size.

In March 2014, the abdominal CT scan identified 20 x 18 mm oval mass with marginal calcification without evidence of enhancement. Nearby pancreatic head there was a hyperdense mass of 5 mm. In lesser curvature of the stomach area there was a tumor of 9 x 7 mm in size (Fig.3).

The patient had complained about persistent pruritus of the entire body since April 2014. Physical examination revealed nonspecific, migratory erythematous skin lesions, which involved face, chest, abdomen and limbs. She was treated with various unguents and creams without relief of the symptoms. Somatostatin injections slightly relieved symptoms for a short time. Chromogranin A concentration was still in the normal range (37,8ng/ml).

In September 2014, a 63-year-old patient was admitted to Department of Endocrinology, Diabetology and Internal Medicine of Medical University of Bialystok to prepare for peptide receptor radionuclide therapy (PRRT). The patient's insulin demand dropped (down to 8 units per day), so insulin therapy was interrupted and glimepiride 2 mg once a day was administered. Based on thyroid ultrasound and laboratory findings, nontoxic multinodular goiter was diagnosed. Ultrasound guided fine-needle aspiration biopsy results indicated benign lesions. Due to pruritus an antihistamine, a tranquillizer and an alpha lipoic acid were prescribed. Although the patient's adherence was good, there had been no significant improvement.



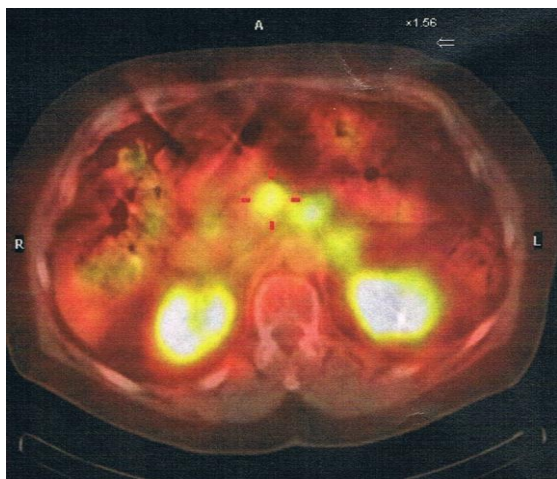
**Figure 4.** January 2015. 18FDG PET-CT - mild 18F-FDG uptake by the mass in the pancreatic body's area.

In October 2014, the 18FDG PET-CT showed mild 18F-FDG uptake by the mass in the pancreatic body's area (19 x 13 mm - smaller than in 2012). In November 2014, the 99mTc-Tektrotide whole body scintigraphy revealed two lesions (27 mm and 17 mm) with expression of somatostatin receptors on the pancreatic body

topography. In December 2014, the CT scan showed two masses: the diameter of the first was 26 mm (previously - 24 mm), of the second - 17 mm (previously - 19 mm). The pancreatic head was polycyclic and enhanced in non-homogenous way.

In January 2015, the patient was admitted to Department of Endocrinology and Isotope Therapy of Military Institute of Medicine in Warsaw for peptide receptor radionuclide therapy. The patient was treated, under the cover of nephroprotection, with intravenous 200mCi <sup>177</sup>Lu-DOTA-TATE (3,7 GBq) (Fig.4). This treatment was repeated in April and July 2015. After PRRT the chromogranin A concentration stayed in the normal range (69,2ng/ml).

In July 2015, the patient was admitted to Department of Endocrinology, Diabetology and Internal Medicine due to bad glycemic control (glucose concentration from 36 to 280 mg%). Laboratory measurements demonstrated elevated LDL-cholesterol level. HbA1c was in recommended range (7,0 %). Abdominal ultrasound detected steatohepatitis. Hypoglycemic therapy was modified. Apart from glimepiride 2 mg once a day, metformin 850 mg three times a day was added.

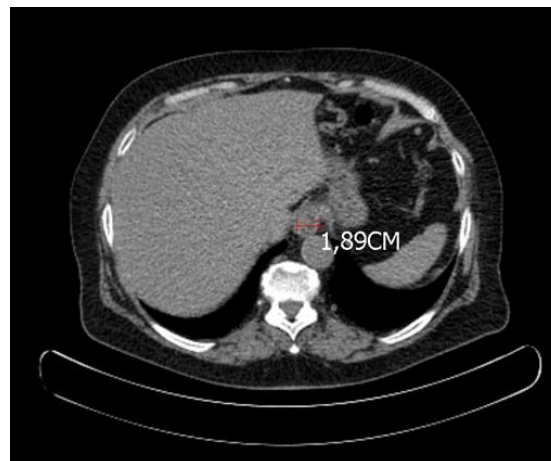


**Figure 5** November 2015. SPECT-CT of the abdomen revealed Lu-177 uptake by two points (diameters: 24 mm and 23 mm) in pancreas area.

In November 2015, the Lu-177 whole body scintigraphy and SPECT-CT of the abdomen revealed Lu-177 uptake by two points (diameters: 24 mm and 23 mm) in pancreas area (Fig.5). Peptide receptor radionuclide therapy has been modified and the patient received 90Y/<sup>177</sup>Lu-DOTA-TATE (1,85 GBq + 1,85 GBq). During PRRT the pruritus had become progressively lesser. Currently there was no sign of cutaneous disease.

In February 2016, the abdominal PET-CT scan showed a pancreatic body mass of 18,9 mm (Fig.6). Minimal reduction of tumor size

and stabilization of proliferative disease were obtained.



**Figure 6.** In February 2016, the abdominal PET-CT scan - a pancreatic body mass of 18,9 mm.

## DISCUSSION

Glucagonoma is a remarkably rare neuroendocrine tumor with estimated incidence 1 in 20 million [3] and is 1% of all pancreatic NETs [7]. Glucagonomas, due to oversecretion of glucagon are associated with a characteristic paraneoplastic phenomenon, called glucagonoma syndrome [8]. It's characteristic features are: necrolytic migratory erythema (NME), weight loss, DM or glucose intolerance, mucosal abnormalities (such as glossitis, cheilitis, stomatitis), diarrhea [4]. Patients may also present normochromic normocytic anemia, hypoaminoacidemia, deep vein thrombosis or pulmonary embolism and neuropsychiatric disturbances (from which depression is most often) [5]. In the literature this syndrome may be also presented as 4D syndrome, which stands for dermatosis, diabetes, deep vein thrombosis and depression [7]. Our patient presented NME, weight loss and DM.

Although earlier studies suggest female predominance (3-4 : 1 female : male), a recent review suggests no gender predilection [9], with the median time of diagnosis in their sixth decade of life [5,3]. The diagnosis of glucagonoma should be based on elevated serum glucagon level and visualization of the pancreatic tumor [9]. Glucagonoma most often is found in the tail of the pancreas [5,3,6]. In our patient's case there was a mass lesion in the pancreatic body. The tail of the pancreas was invisible in USG and CT, probably atrophied.

Glucagonoma is slow-growing and rather low-malignancy tumor [8]. Ki-67 is routinely used as a static marker of proliferative activity. The fraction of Ki-67-positive tumor cells (the Ki-67 labeling index) is often correlated with the clinical

course of the disease. The histopathologic report in our case revealed Ki 67 - 2% and confirmed low-malignancy of this tumor.

However, delays in diagnosis are common [9] and remain a major problem in the treatment of this tumor [8]. This is probably related to extreme rarity of glucagonoma, under-recognition of NME, the fact that skin biopsy is a poor diagnostic tool for diagnosing NME and due to the lack of specificity of the other symptoms [5,9]. For these reasons glucagonomas are characteristically large tumors (> 5cm) [4] and in more than half of cases metastatic at the time of diagnosis [4,8]. The most frequent site of metastasis is the liver [3]. Our patient had metastases to regional lymph nodes. The median time between the onset of symptoms to diagnosis is 3-4 years [5].

The hallmark of glucagonoma is NME. It manifests in approximately 70% of patients [10]. Its pathogenesis remains unknown, but hypoaminoacidemia and other nutritional deficiencies, such as essential fatty acids or zinc are taken into consideration [6,10]. The NME rash starts as annular pattern of erythema and progresses to bullae, ulcers and crusts [7,8]. It has a characteristic distribution – the lesions are most often seen in the perigenital regions, although they can also be found on the trunk, lower limbs, perioral region and sites of minor trauma [2,10]. The differential diagnosis includes such dermatological diseases as contact dermatitis, indertrigo, acrodermatitisenteropathica, pellagra, psoriasis, eczema, pemphigus and seborrheic dermatitis [9,10]. Very often the correct diagnosis is delayed [10]. The early recognition of NME is very important and may lead to better prognosis, because it is often the only and the first manifestation of the glucagonoma syndrome. Our patient presented uncharacteristic skin lesions with persistent, migratory pruritus.

Diabetes mellitus is present at the onset of symptoms in 40% of patients, but 80% will develop it in the course of the disease [8,9]. In our patient case, DM had preceded glucagonoma diagnosis by 2 years. Its course is usually mild, although most patients require insulin therapy [3]. Therapy of our patient was modified several times. She has been treated with oral hypoglycemic agents and insulin during her disease. Currently she is treated with metformin. Her last HbA1c concentration was 7,0%. Hyperglucagonemia affects glucose metabolism. It inhibits glycolysis and glycogen synthesis and stimulates hepatic gluconeogenesis [9]. Moreover it antagonizes the effect of insulin [6].

If NME and DM come together, the proper diagnosis can be faster [3]. In this case the diagnosis had been made after surgery and histopathological examination and NME occurred two years after diagnosis.

The best treatment strategy of glucagonoma is surgical removal of the tumor [11]. Surgical approach depends on location, size and pathological type of the tumor and it can be divided into local resection, pancreatoduodenectomy or pancreatic body and tail resection [11]. Unfortunately surgery is often impossible, due to expansive involvement of hepatic parenchyma or bilobar hepatic metastases [7]. In our patient case, due to infiltration into splenic artery and vein, the surgery was subtotal. In such cases non-surgical therapies play a great role in palliative treatment and relieving symptoms.

The base of that treatment are somatostatin analogs [12]. Somatostatin inhibits glucagon secretion, but due to 2-minute half-life it can't be used in daily clinical practice. Therefore longer-acting somatostatin-analogs, such as octreotide and lanreotide have been developed [12]. They can be used if somatostatin receptors are present in histological examination or the Octreoscan is positive [7]. They allow to control NME in 50-90% cases and they also relieve other symptoms, like weight loss, abdominal pain and diarrhea [4]. In this case somatostatin injections slightly relieved skin symptoms for a short time. Moreover, the patient stopped complaining about abdominal pain and weight loss. Unfortunately, somatostatin analogs do not improve the course of diabetes [4]. Due to deterioration of DM, our patient required hospitalization and changing the treatment from insulin therapy and glimepiride to metformin treatment. Somatostatin may also have apoptotic and cytostatic effects [12]. It has been shown that octreotide can inhibit tumor growth in patients with midgut NETs [7,12]. When these analogs are used for more than 12 months, tachyphylaxis may occur [12]. Our patient has been treated on average once a month with 30mg of somatostatin since December 2013 and there weren't any changes of the dose since the beginning of this therapy.

A relatively new therapeutic option is peptide receptor radionuclide therapy. Malignant cells of the tumor express a high number of somatostatin receptors [13]. By using appropriate vectors and linkers with hard beta-emitting yttrium or lutetium, it enables identification of the tumor and, what is more important, destruction of cells with somatostatin receptors [7]. Previous studies has shown that PRRT may substantially improve the quality of life in patients with SSTR-positive tumors [13]. The case of our patient seems to confirm that. So far she has received three doses of 200mCi <sup>177</sup>Lu-DOTA-TATE and one dose of 90Y/<sup>177</sup>Lu-DOTA-TATE. Pruritus and skin lesions have decreased during this therapy and currently there is no sign of cutaneous disease. The patient's quality of life improved.

## CONCLUSIONS

Peptide receptor radionuclide therapy, by reducing bothersome symptoms, may substantially improve the quality of life in patients with SSTR-positive tumors. Moreover, due to selective concentration in tumor cells, it allows to obtain stabilization of proliferative disease.

## Conflicts of Interest

The authors declare that there is no conflict of interest that could be perceived as prejudicing the impartiality of the review reported. All authors declare any financial or other potential conflict of interest.

## Funding

This research did not receive any specific grant from any funding agency in public, commercial or not-for-profit sector.

## REFERENCES

1. Santacroce L, Abraham MR, Diomede L. Glucagonoma. Medscape [Internet]. 2015 May Available from: <http://emedicine.medscape.com/article/118899-overview#showall> [cited 2016 Jun 11]
2. Cardoso Filho Fde A, Feitosa RG, Fechine CO, Matos CM, Cardoso AL, Cardoso DL. Glucagonoma syndrome associated with necrolytic migratory erythema. *Rev Assoc Med Bras.* 2015 May-Jun;61(3):203-6.
3. Wermers RA, Fatourehchi V, Wynne AG, Kvolts LK, Lloyd RV. The Glucagonoma Syndrome. Clinical and Pathologic Features in 21 patients *Medicine (Baltimore)*1996;75:53–63.
4. Ito T, Igarashi H, Jensen RT. Pancreatic neuroendocrine tumors: clinical features, diagnosis and medical treatment: advances. *Best Pract Res Clin Gastroenterol.* 2012 Dec;26(6):737-53.
5. Eldor R, Glaser B, Fraenkel M, Doviner V, Salmon A, Gross DJ. Glucagonoma and the glucagonoma syndrome – cumulative experience with an elusive endocrine tumor. *Clin Endocrinol.* 2011;74:593–8.
6. Yao JC, Eisner MP, Leary C, Dagohey C, Phan A, Rashid A, Hassan M, Evans DB. Population-based Study of Islet Cell Carcinoma *Ann Surg Oncol.* 2007;14:3492–500.
7. Vinik A, Feliberti E, Perry RR. Glucagonoma Syndrome. *Endotext* [Internet]. South Dartmouth (MA): MDText.com, Inc.; 2000-2014 Aug 27. Available from: <http://www.ncbi.nlm.nih.gov/books/NBK279041/> [cited 2016 Jun 11]
8. Wei J, Lin S, Wang C, Wu J, Qian Z, Dai C, Jiang K, Miao YI. Glucagonoma Syndrome: a case report. *Oncol Lett.* 2015 Aug;10(2):1113-1116.
9. Ashraf Al-Faouri, Khaled Ajarma, Samer Alghazawi, Sura Al-Rawabdeh, and Adnan Zayadeen, “Glucagonoma and Glucagonoma Syndrome: A Case Report with Review of Recent Advances in Management,” *Case Reports in Surgery*, vol. 2016, Article ID 1484089, 3 pages, 2016. doi:10.1155/2016/1484089
10. Fang S, Li S, Cai T. Glucagonoma syndrome: a case report with focus on skin disorders. *Onco Targets Ther.* 2014 Aug 14;7:1449-53.
11. Lv WF, Han JK, Liu X, Wang SC, Pan BO, Xu AO. Imaging features of glucagonoma syndrome: a case report and review of the literature. *Oncol Lett.* 2015 Apr;9(4):1579-82.
12. Kunz PL, Fisher GA. Advances in the treatment of gastroenteropancreatic neuro-endocrine tumors. *Clin Exp Gastroenterol.* 2010;3:79-86.
13. Traub-Weidinger T, Raderer M, Uffmann M, Angelberger P, Kurtaran A, Leimer M, Preitfellner J, Dudczak R, Virgolini I. Improved Quality of Life in Patients Treated with Peptide Radionuclides. *World J Nucl Med.* 2011 Jul; 10(2):115-21.